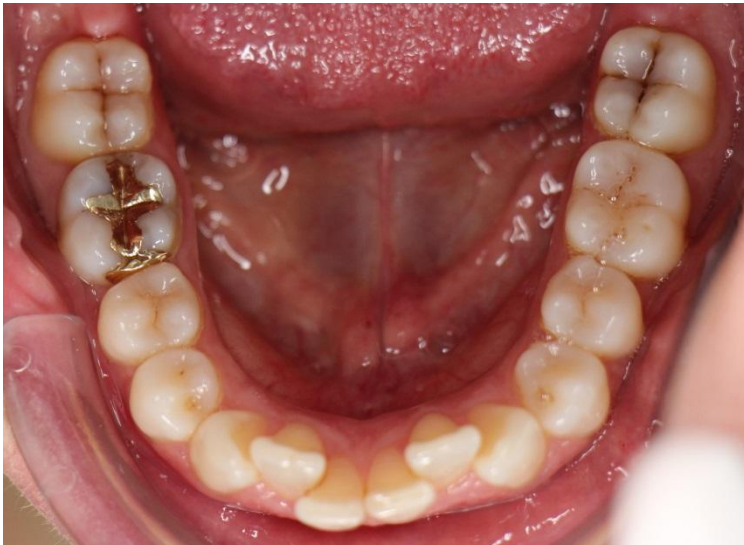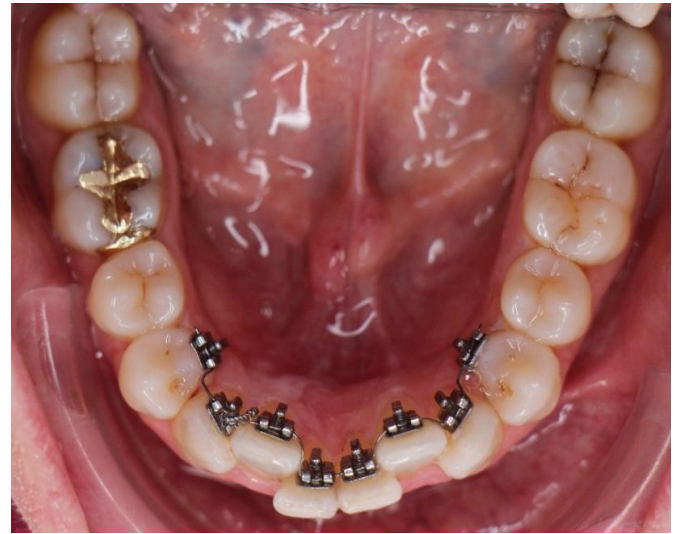


Engstand der Frontzähne

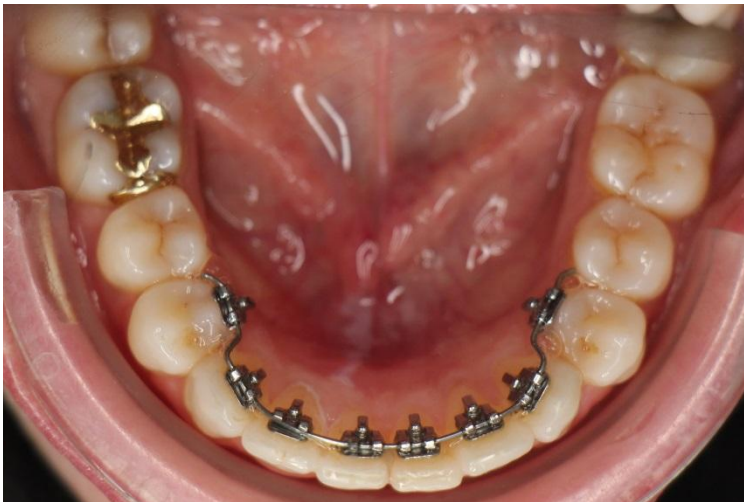



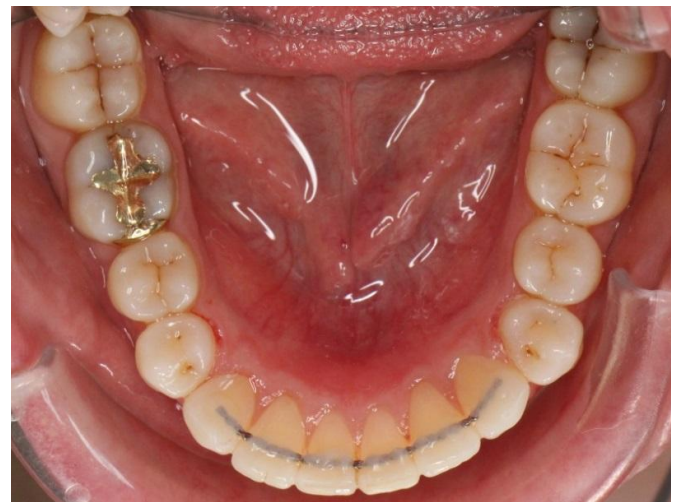20.8.2013



10.9.2013



24.3.2013



9.7.2013



Patientin 37 J.