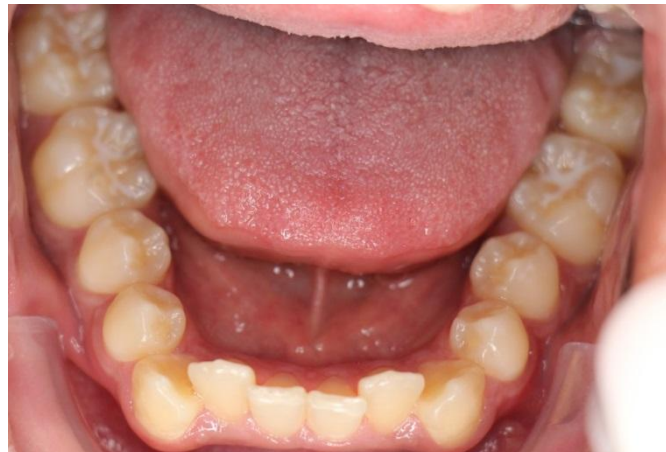
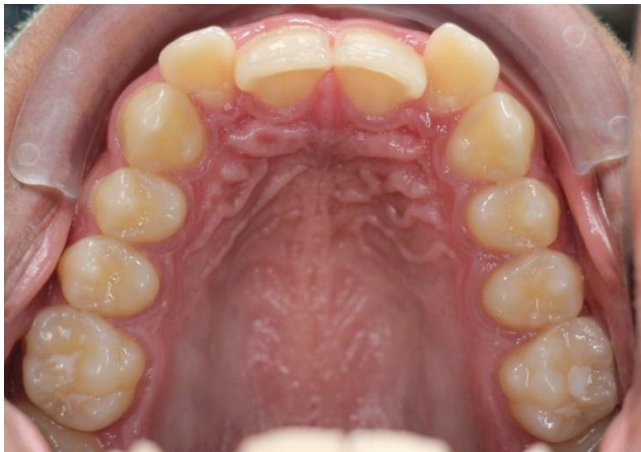
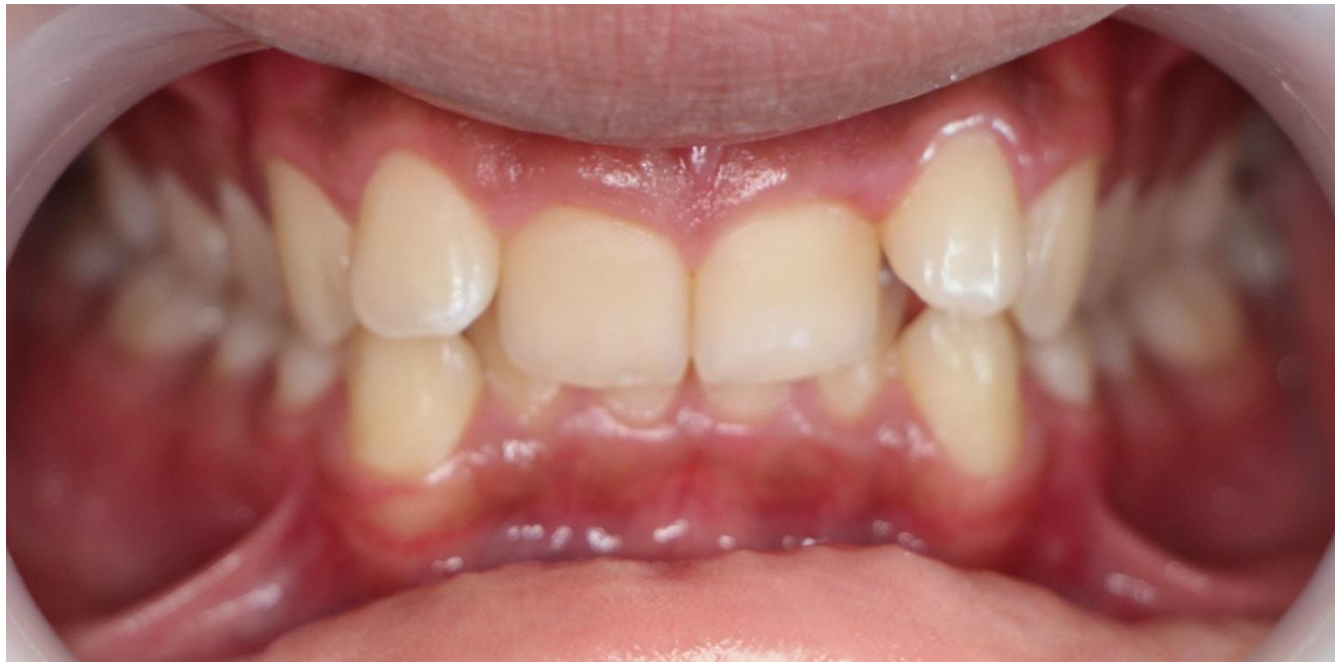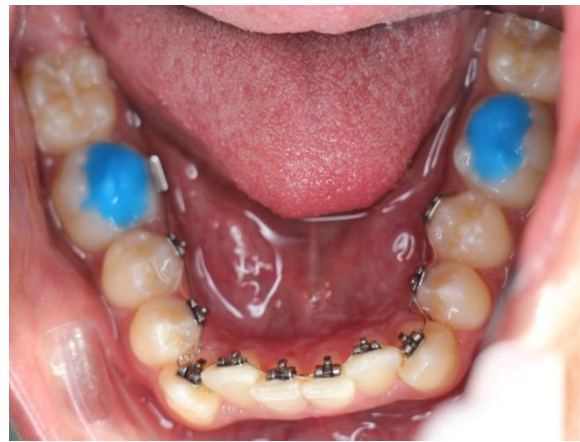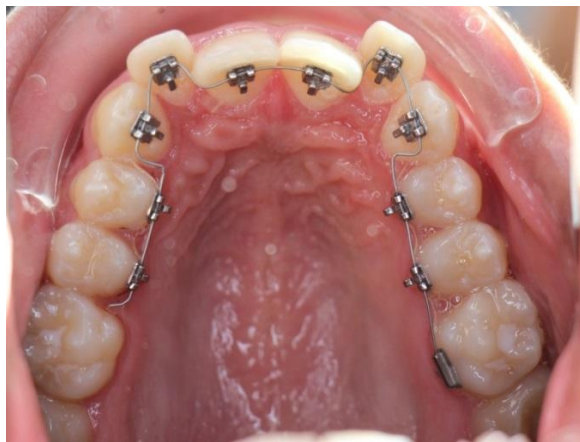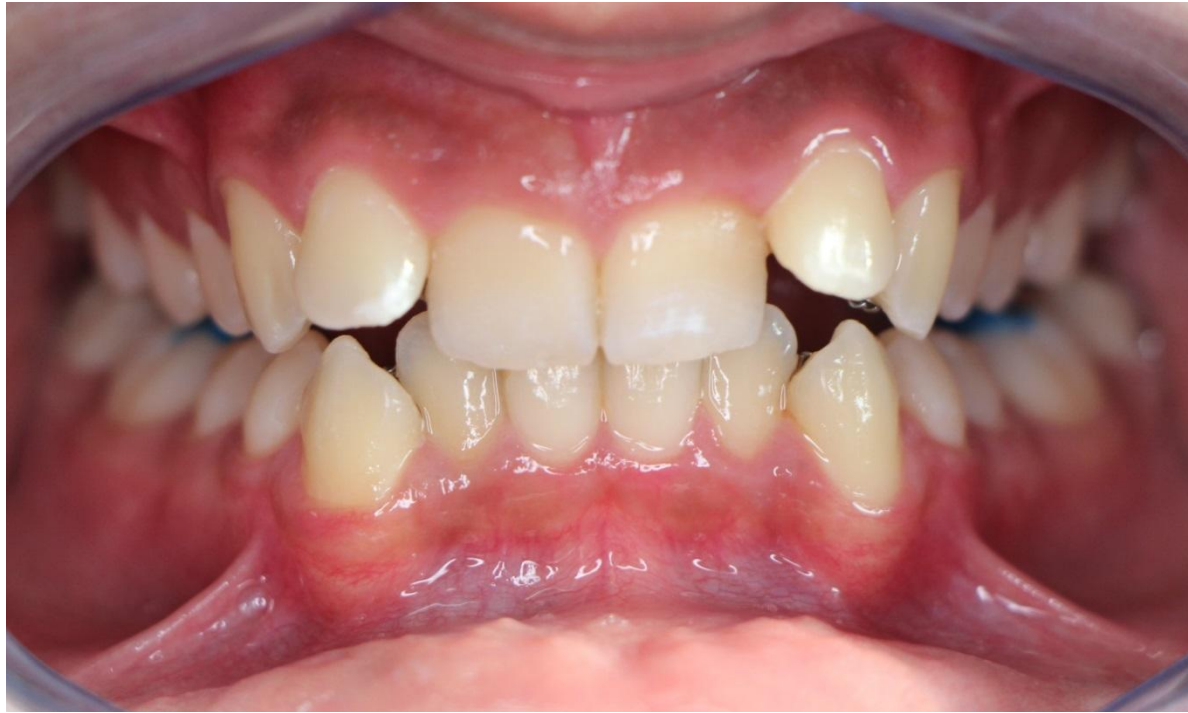Tiefbiss, Engstand



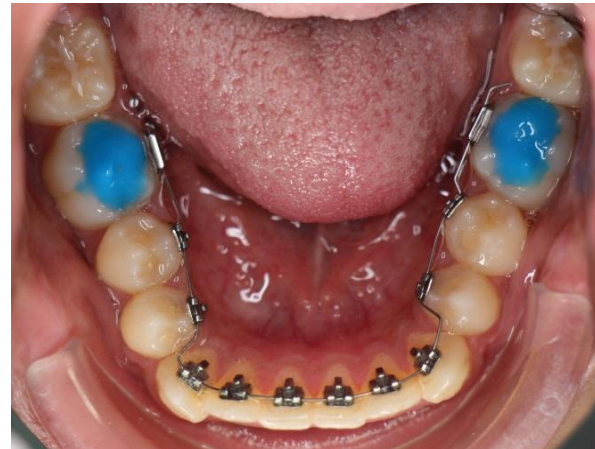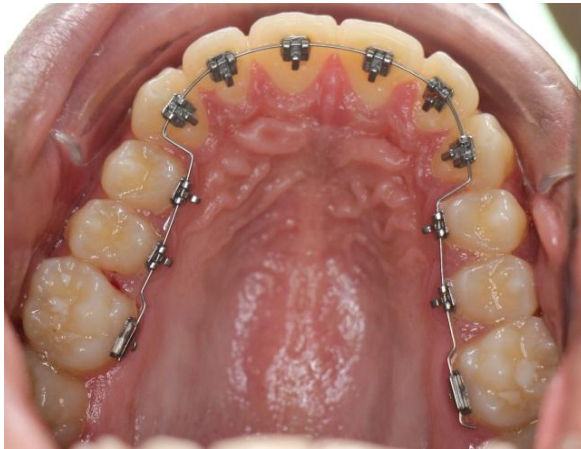

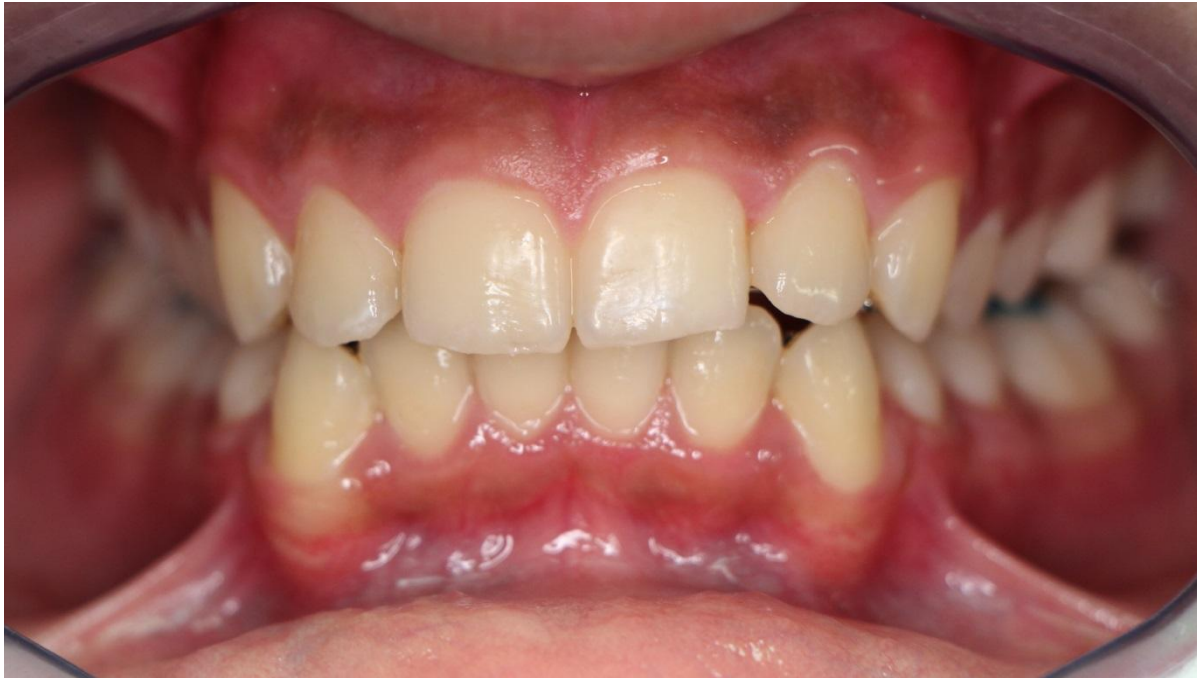
Patient 16 J. 28.8.2013

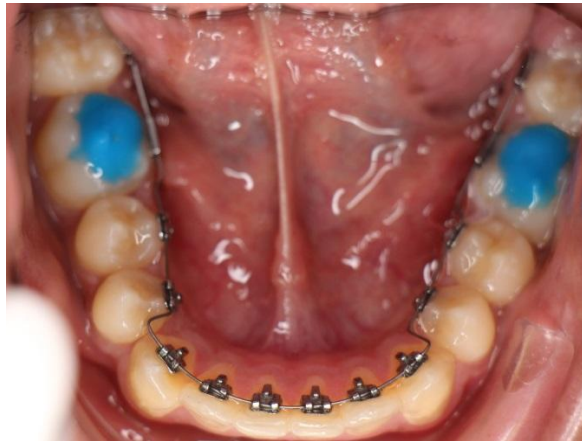
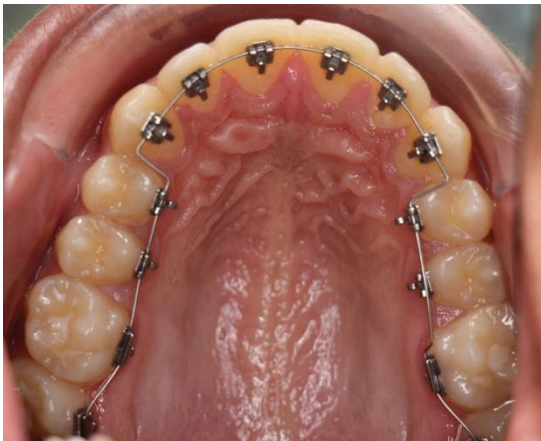
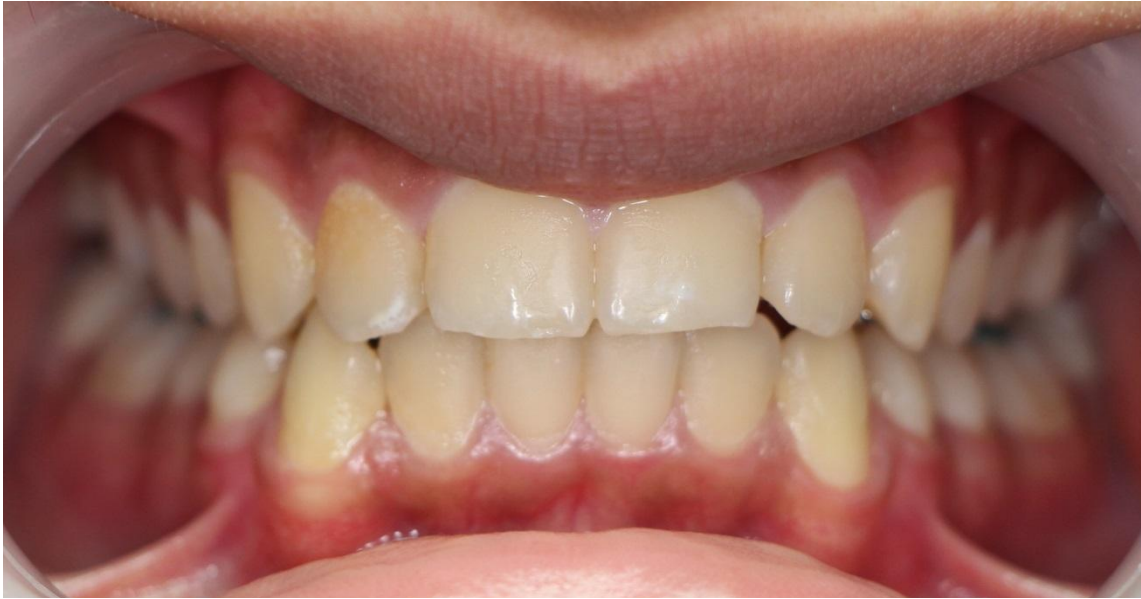
Patient 16 J. 19.9.2013





Patient 16 J. 5.11.2013



Patient 16 J. 10.12.2013