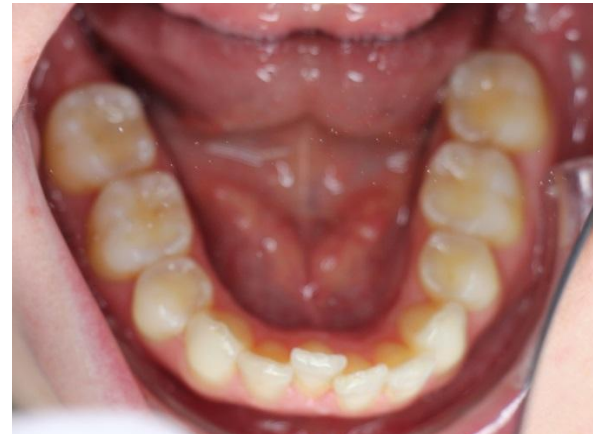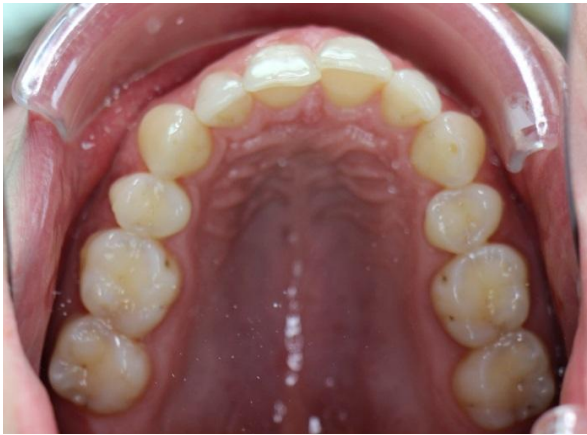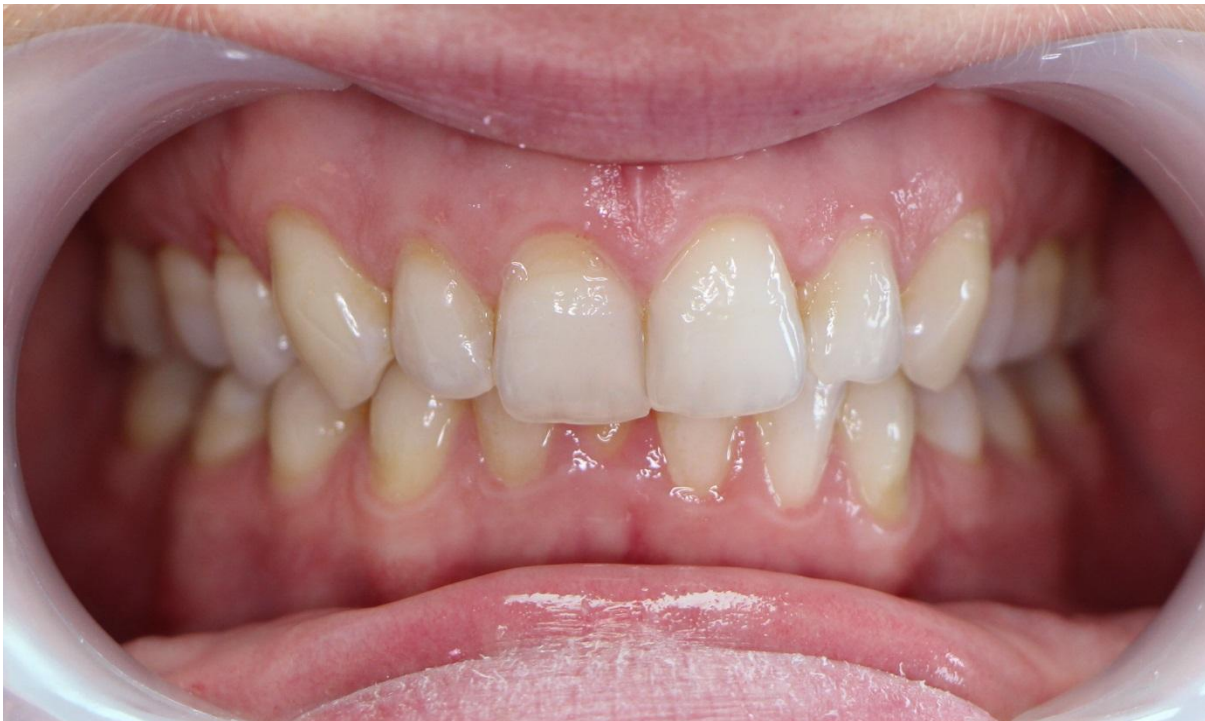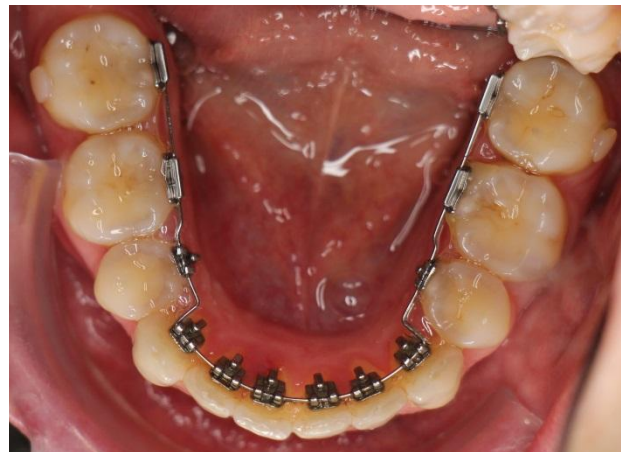


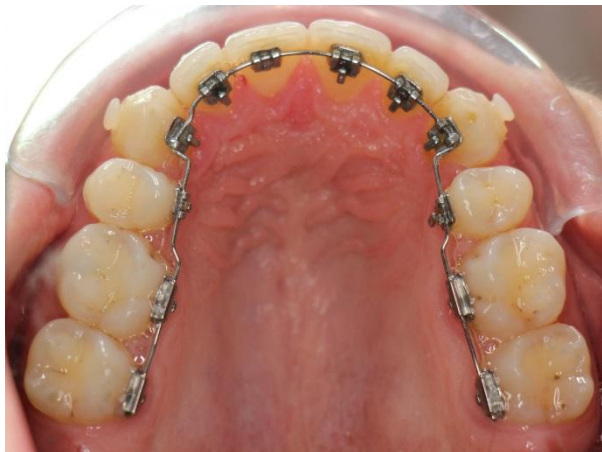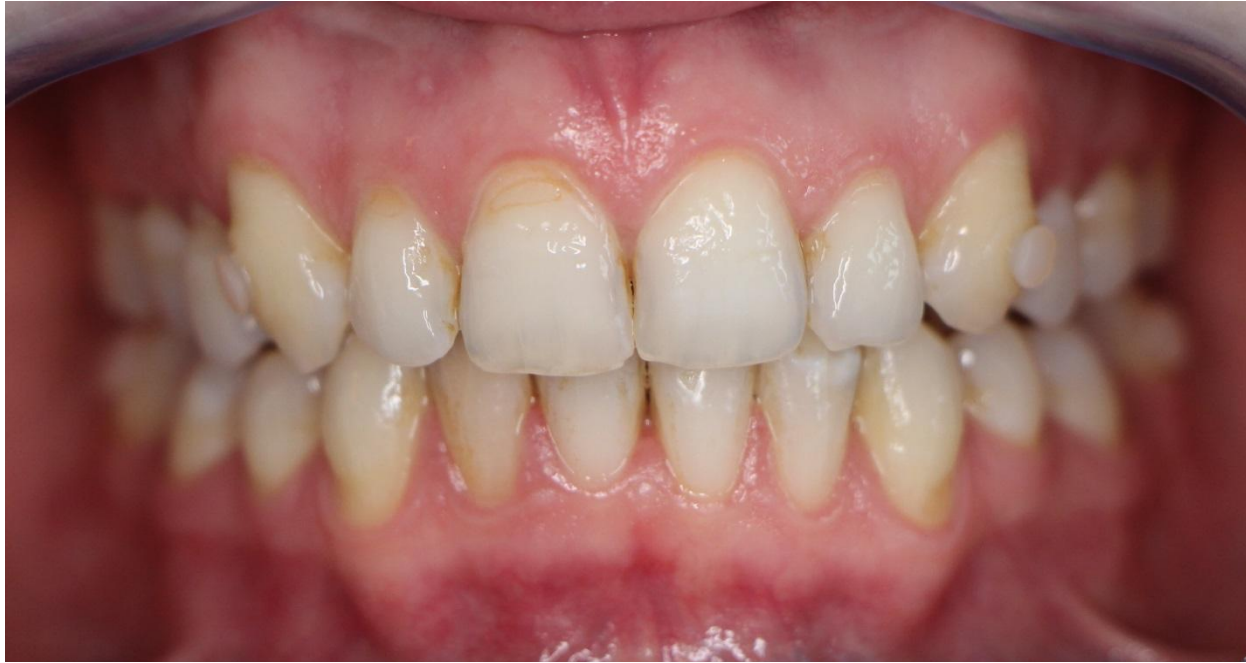Tiefbiss, Engstand

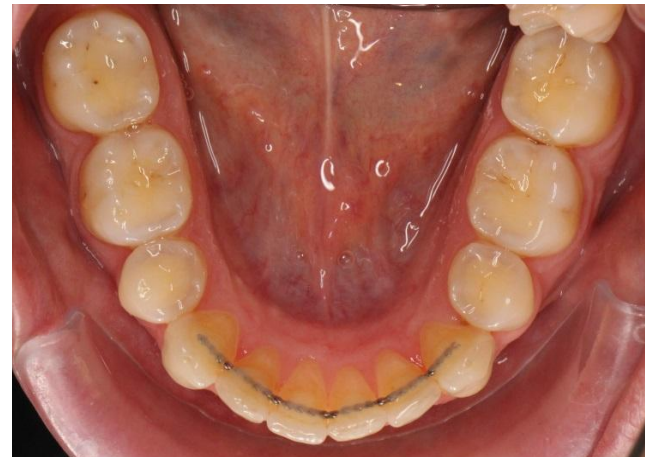
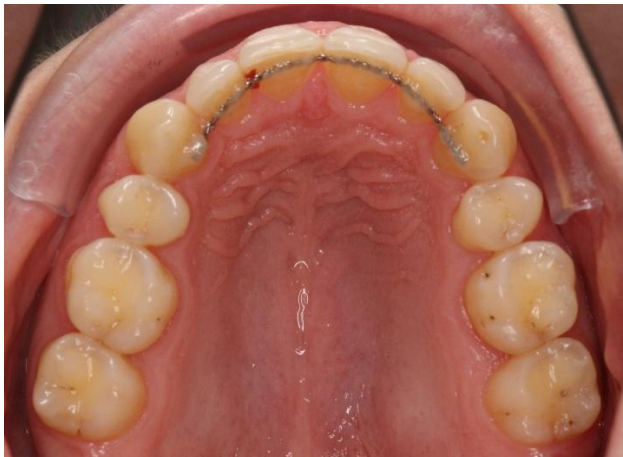
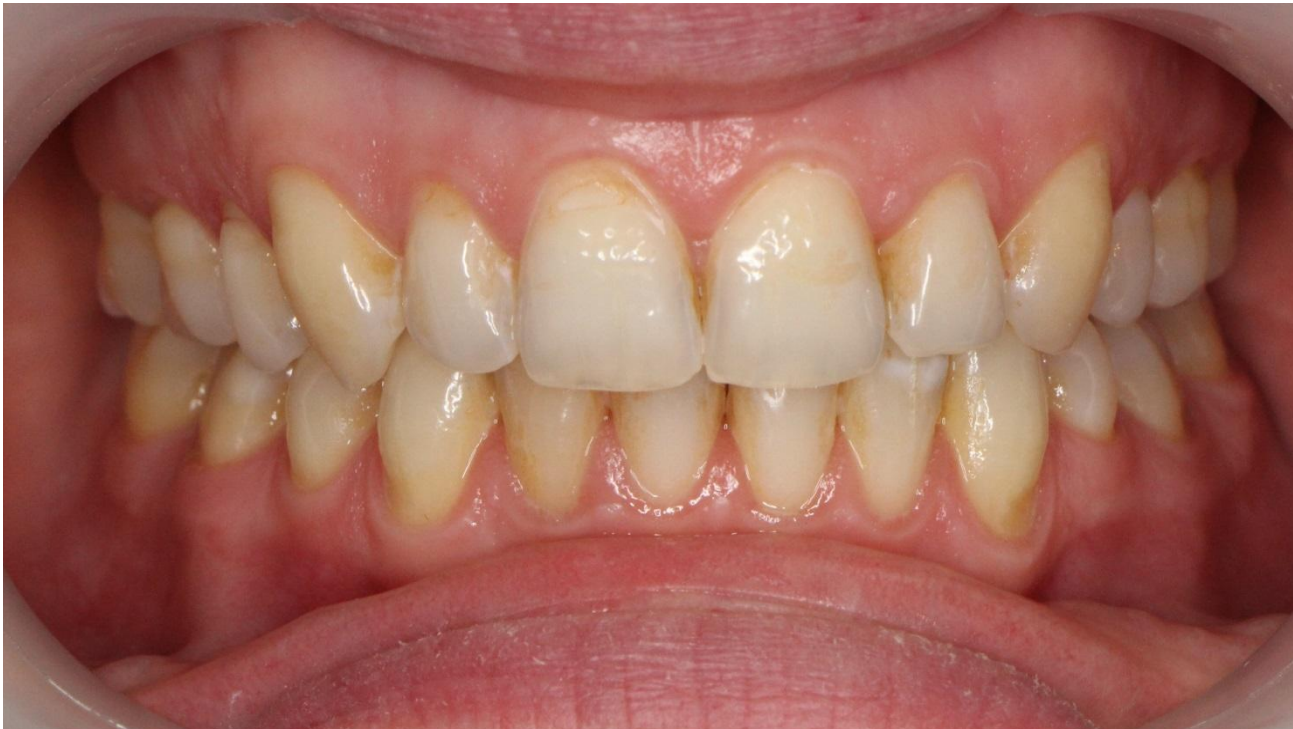


Patientin 34 J. 25.4.2013



Patientin 34 J. 11.9.2013



Patientin 35 J. 7.3.2014

